



مستشفى الملك فيصل التخصصي ومركز الأبحاث  
**King Faisal Specialist Hospital  
and Research Centre**

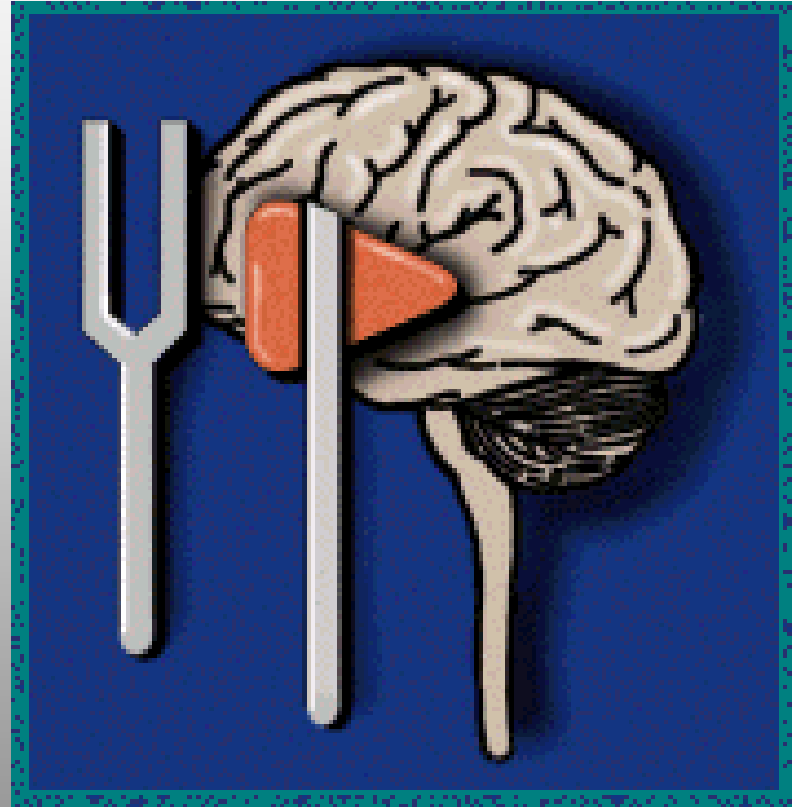


# Hints in Neurology Exam

Omar M. Wazzan, M.D  
Neurosciences Department  
KFSH&RC-J

Non-Neurology Symposium

KFSH & RC-J October.2003







# Why?

- Not costly
- Very yielding
- But you need to **do** & do it **wright!**

# CNS Exam

- No focality
- Intact
- Grossly normal
- Often means **NOT** done!

# Neuro-Exam

- MS
- CN
- Motor
- Sensory
- Coordination
- DTR
- Gait

# MS

- Alert-----describe what pt can or can not do
- Memory--STM---but 3 objects Ab
- Aphasia

# Aphasia

- Broca's
- Motor
- Expressive
- Non-fluent
- Frontal
- Ant.
- Production

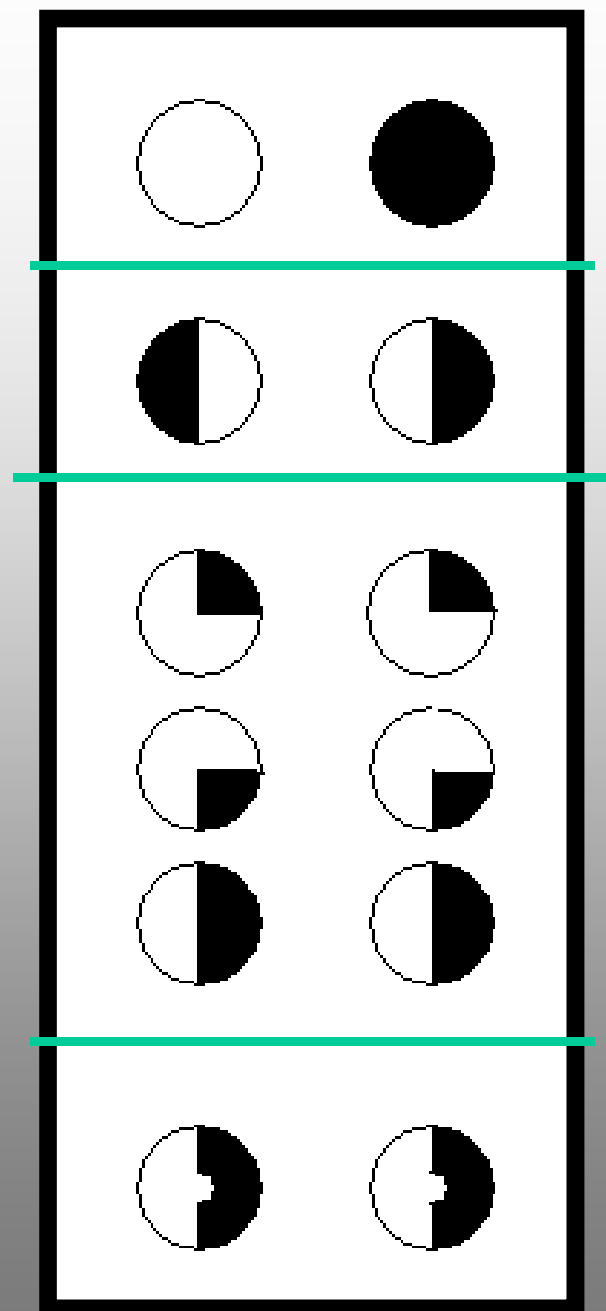
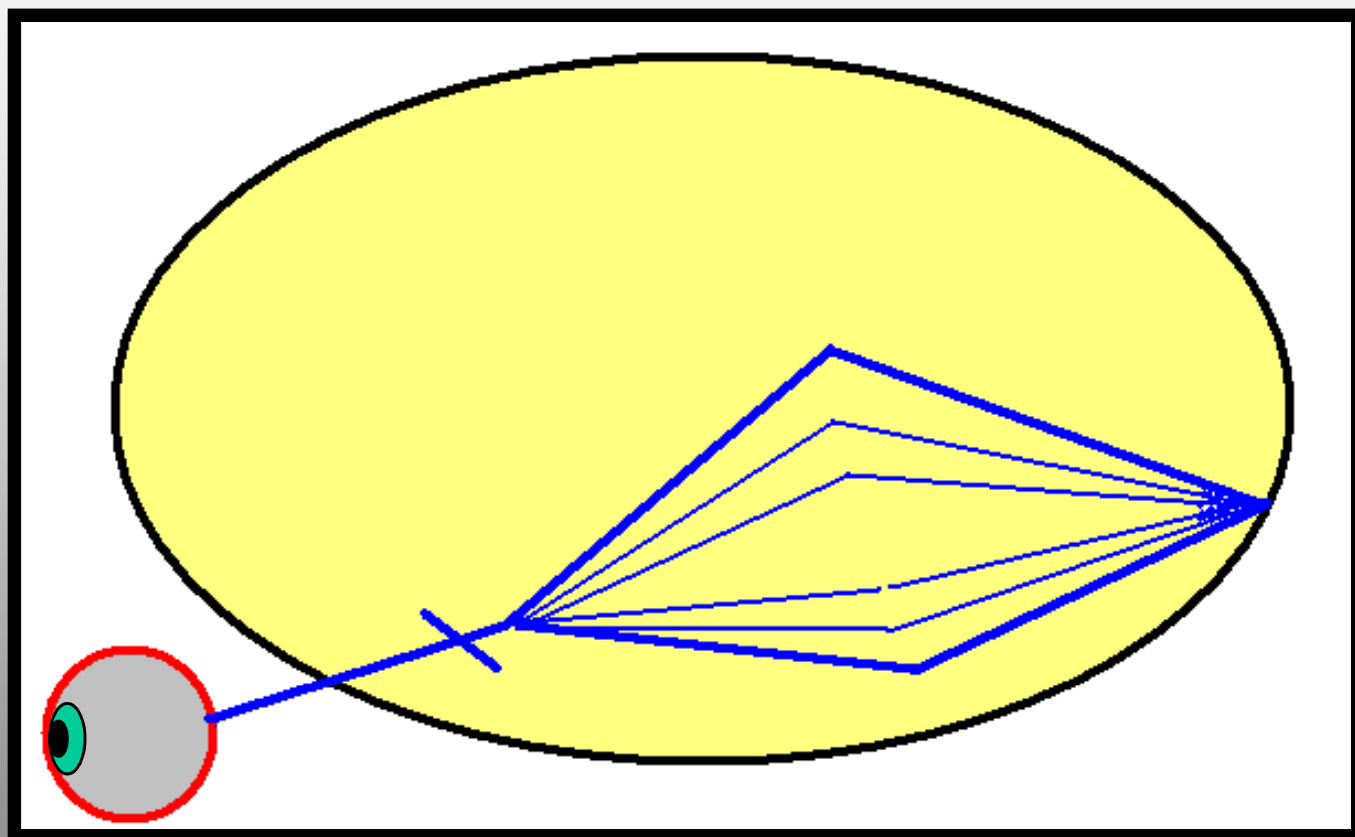
- Wernicke's
- Sensory
- Receptive
- Fluent
- Temporal
- Post.
- Comprehension

Both-----Global

Both-----MCA

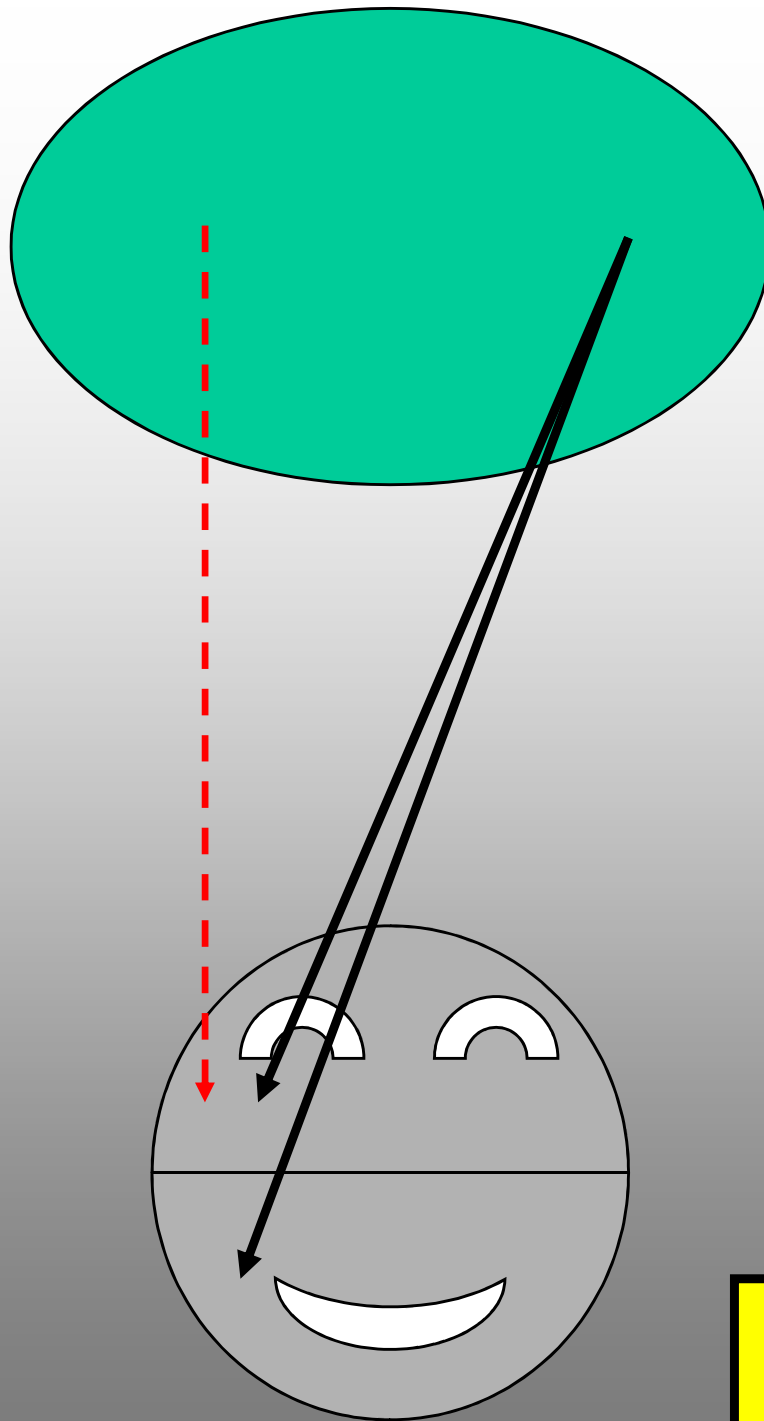
Anomia-----Metabolic, ALZ

Normal repeat-----Transcortical aphasia



# CN

- Pupils-----Flash light
- Ptosis-----complete---III
- III-----dilated pupil---aneurysm  
normal-----ischemic (DM)
- VII----- what side does not move  
Bell's palsy---protect **eyes** not electrical
- Corneal-----**Colored** (attractive part)  
most **sensitive** in V neuropathy not neuralgia
- Gag-----annoying, Bilat, smoking
- Tongue-----rarely deviates! But **VII** makes XII



For simple person  
like me!!!



# MOTOR

- Spasticity---all the way-----pyramid---stroke
- Rigidity-----bombing-----extrapyr---Parkinson

One million Reyal test!!!!!!!!!!!!!!

- Tremor-----at rest-----resting---Parkinson  
all the way-----action---ET  
onset & end-----intentional---cerebellar
- Hidden weakness-----pronator drift  
fine movts.  
ICU---one side withdrawal

# DTR

**The honest teller!**

- Not hyper not hypo but **asymmetry**
- Know your Ab from syx & Signs
- Clonus always Ab

Bilat ankle areflexia-----PN

- Plantar ↑ always Ab, but do it Wright

Bil ↑ ↑ alert----- spinal stenosis  
comatose-----SZ

# Sensory

Ignore (Yasalam!)

- Sensory level-----Spinal cord
- Stocking-glove-----PN

# Coordination

- FNF
- HTS

# GAIT

The most important single part of Neuro-Exam

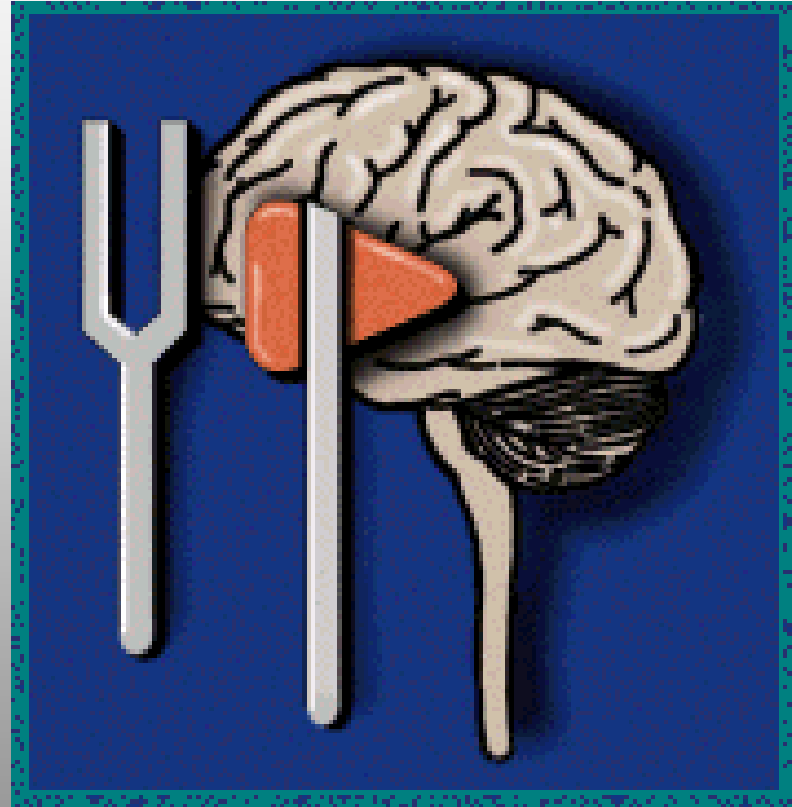
- Circular-----stroke
- Ataxic-----wide base, fall
- Parkinson-----short, stooped, en bloc
- Steppage-----high leg (PN)
- Waddling-----side to side (Myopathy)
- Scissor-----spastic (CP)
- Apraxic-----slow, magnetic (Frontal)

Hysterical-----circus, fun to watch!!!

# & #

- Sensory
- Motor
- DTR

شكرا



THANKS!